

# An Incidentally Detected Venous Malformation of the Uterine Cervix: Case Report

Yeşim BAYOĞLU TEKİN<sup>1</sup>, Recep BEDİR<sup>2</sup>, Emine Seda GÜVENDAĞ GÜVEN<sup>1</sup>

Rize, Turkey

## ABSTRACT

Venous malformations of the uterine cervix are extremely rare. Most lesions are asymptomatic and incidental, however sometimes, they may present with abnormal vaginal bleeding. We aimed to describe a case of venous malformation of the uterine cervix and discuss the differential diagnosis and clinical management of this entity.

**Keywords:** Uterine cervix, Venous malformation, Vascular malformation, Benign uterine cervical disease

Gynecol Obstet Reprod Med 2015;21:169-170

## Introduction

This report describes venous malformation (VM) of the uterine cervix is an extremely rare localization of the vascular lesion that involves the female genital tract.<sup>1</sup> Venous malformations are accepted as congenital vascular defects that are sensitive to the hormonal changes and can slowly enlarge over the years. VM grows up rapidly and becomes symptomatic by infection, trauma and thrombosis. However most VM are asymptomatic or incidentally find.<sup>2</sup> The symptomatic lesions are presented with abnormal vaginal bleeding differ from postcoital spotting to intractable vaginal bleeding. The incidence of this curious lesion of the female lower genital tract is unknown; most of the cases are presented as case reports in the literature.

## Case Report

A 46-year-old woman was referred to our hospital for the evaluation of the abnormal Pap test which was "Low grade intraepithelial lesion." She had regular menstrual cycles and her gynecological history was unremarkable. Colposcopic examination was performed and purple colored, well-circumscribed lesion with a diameter 10x15 mm at 10 o'clock was visualized

at the uterine cervix with the absence of acetowhite lesion (Figure 1). The loop electrosurgical excision procedure was carried out for local excision of the lesion. During the surgical excision heavy bleeding was occurred and controlled with electrocoagulation and suturing.

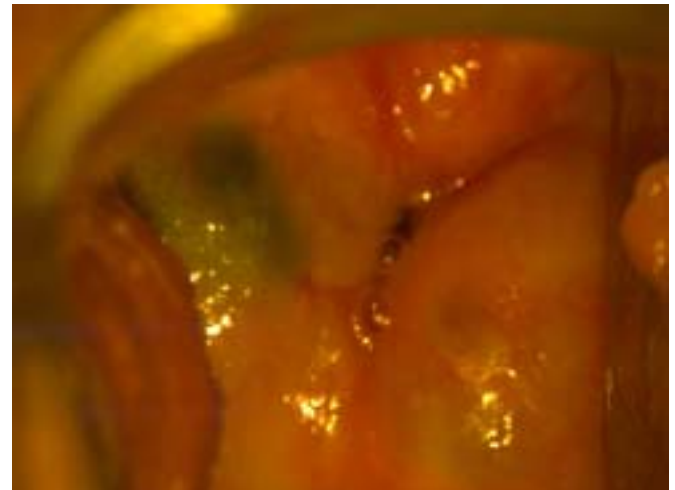


Figure 1: Uterine cervix was hyperthrophic and irregular due to previous vaginal deliveries. The lesion was seen purple colored, well-circumscribed with a diameter of 10x15 mm at 10 o'clock by colposcopic examination

The excisional biopsies were evaluated by the pathology laboratory. The final report was VM as dilated, congested, irregular vessels with flat endothelial lining and chronic cervicitis at the surface epithelia (Figure 2). Cellular pleomorphism, atypia and mitotic figures were absent and the thin endothelial elements were stained with CD 31 and CD 34. She discharged at the second day of the operation without vaginal bleeding. After three months from the surgery the cervix had normal appearance and there was no sign of the residual lesion on speculum examination and transvaginal ultrasonography.

<sup>1</sup> Department of Obstetrics and Gynecology Recep Tayyip Erdoğan University, School of Medicine, Rize

<sup>2</sup> Department of Pathology Recep Tayyip Erdoğan University, School of Medicine, Rize

Address of Correspondence: Yeşim Bayoğlu Tekin  
Recep Tayyip Erdoğan University School  
of Medicine Department of Obstetrics  
and Gynecology Rize, Turkey  
yesimbay@yahoo.com

Submitted for Publication: 17. 07. 2014

Accepted for Publication: 11. 08. 2014

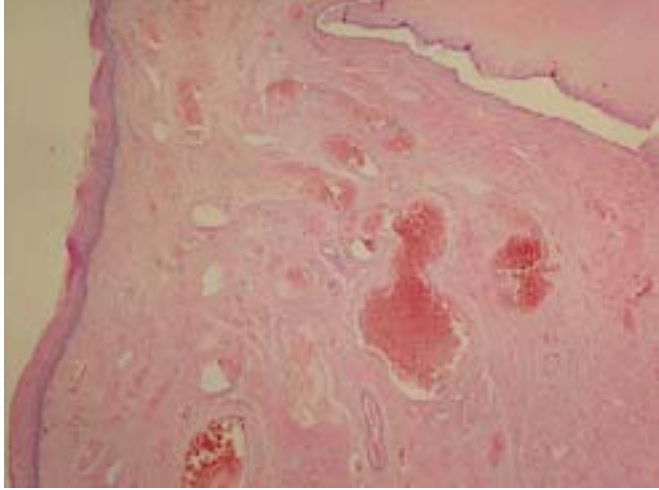


Figure 2: Dilated, congested, irregular vessels with flat endothelial lining and chronic cervicitis at the surface epithelia (hematoxylin-eosin, x200).

## Discussion

The symptomatic cervical venous malformations were observed as grape-like purple, non-pulsatile smooth masses that could be compressed and discolored with pressure and enlarged with Valsalva maneuver.<sup>3</sup> Diagnostic tests as color Doppler ultrasonography, magnetic resonance imagination (MRI) and angiography are helpful for differential diagnosis. At color Doppler ultrasonography the lesion is imaged as well-defined hyperechogenic nodules with abundant vessel flow, dilated venous channels and arterial channels showing low-resistance flow. MRI and angiography could be performed for imaging localization and extension of the lesion. Differential diagnosis is significant to distinguish VM of the cervix from other rare conditions of the cervix like hematomas, varicosities, endometriosis, choriocarcinoma and malignancies. Histopathological sections reveal dilated tortuous vascular structures with single layer endothelial lined and thinner walled venous vessels filled with clots and surrounded by scattered smooth muscle fibrils. Conservative treatments including local excision conization, trachelectomy, thermal cautery, cryotherapy, and CO<sub>2</sub> laser excision are the first choice for young woman with localized lesion to preserve the

fertility with the risk of persistence and relapse.<sup>4</sup> Surgery is seen the proper option for older patients with wide extend of the lesion or unsuccessful treatment with embolization. Hence the procedure can be tailored to the patient according to the size and spread of the vascular malformation. Nonetheless hysterectomy can associate with hypogastric artery ligation or preoperative embolization for reduction the intraoperative blood loss at diffuse lesions. Our case was found to worth for presentation because it is first incidentally detected case co-existing with abnormal cervical cytology in the literature.

## Rastlantısal Olarak Saptanan Uterin Serviksin Venöz Malformasyonu: Olgu Sunumu

### ÖZET

Uterin serviksin venöz malformasyonu çok nadir olarak görülür. Çođu lezyon asemptomatiktir ve rastlantısal olarak tespit edilir ancak bazen anormal vajinal kanama ile karřımıza çıkabilir. Amacımız, uterin serviksin malformasyonu tespit edilen bir olguyu sunmak ve bu durumun ayırıcı tanısı ve klinik yönetimini tartışmaktır.

**Anahtar Kelimeler:** Uterin serviks, Venöz malformasyon, Benign uterin servikal hastalık

### References

1. Ozyer S, Uzunlar O, Gocmen M, Bal S, Sirvan L, Mollamahmutoglu L. Cavernous hemangioma of the cervix: a rare cause of vaginal bleeding. J Low Genit Tract Dis 2006;10:107-8.
2. Kondi-Pawti A, Kairi-Vassilatou E, Spanidou-Carvouni H, Kontogianni K, Dimopoulou K, Goula K. Vascular tumors of the female genital tract: a clinicopathological study of nine cases. Eur J Gynaecol Oncol 2005;24:323-6.
3. Shu Wang, Jing He Lang , Hui Mei Zhou. Venous malformations of the female lower genital tract. Eur J Obstet Gynecol Reprod Biol 2009;145:205-8.
4. Powell JL, Zwirek SJ, Sankey HZ. Hemangioma of the cervix managed with the Nd: YAG laser. Obstet Gynecol 1991;78:962-4.